


A Professional Courtesy of:

Eddie F. Kadrmas, MD, PhD

Surgical & Medical Retina, Uveitis, Macular Degeneration & Diabetic Eye Disease



**KADRMAS EYE CARE
NEW ENGLAND™**

VISION FOR TODAY • VISION FOR THE FUTURE

40 Industrial Park Road, Plymouth, MA 02360 • 508-746-8600 • Fax: 508-747-0824
3119 Cranberry Highway, Suite 3 • East Wareham, MA 02538
12 West Grove Street • Middleboro, MA 02346
133 Falmouth Road • Mashpee, MA 02649
76 Airline Road • South Dennis, MA 02660

www.plymoutheyecare.com

RETINA DIGEST®

AUTUMN 2016



Repair of Retinal Detachment After Open Globe Injury

Consequences of open globe injuries may include vision loss or eye loss. Outcome studies suffer from significant variation in the severity of injury and timing of retinal detachment development, making prognosis difficult to determine. Reed et al from Wills Eye Hospital, Pennsylvania, undertook a retrospective, consecutive, interventional case series to study the outcomes in cases of retinal detachment repair in severely traumatized eyes. The authors focused on posterior open globe injuries in Zone II (the anterior 5 mm of the sclera) or Zone III (the region posterior to Zone II).

The authors identified 30 patients (age range, 5–81 years; 77% male) who had suffered retinal detachment after surgery for open globe injury and who met the inclusion criteria. Mean follow-up was 25 ± 16 months; mean follow-up from the first surgery after final vitreoretinal surgery was 23 ± 16 months.

Injury types included 21 ruptures, 6 penetrating injuries, 1 intraocular foreign body not requiring immediate pars plana vitrectomy and 2 perforating injuries. Zone III was involved in 20 eyes; the injury was limited to Zone II in the remaining 10 eyes. At the time of open globe injury diagnosis, visual acuity was

- no light perception in 4 eyes
- light perception in 19 eyes
- hand motions in 5 eyes
- counting fingers in 2 eyes

Retinal detachment was diagnosed a median of 6 days after the open globe injury surgery

Inside This Issue

- Anterior Uveitis and Spondyloarthritis Link
- Trends in Global Myopia and High Myopia Prevalence
- Best Timing for Epiretinal Membrane Surgery

Do you or your staff have any questions about Retina Digest? Please write or call our office. We would be happy to hear from you.

©2016



(range, 2–355 days); only 1 patient was lost to follow-up after surgery.

At the time of diagnosis, 27 patients (90%) had vitreous hemorrhage; 24 patients (80%) had hyphema. At the time of surgery, 24 patients (80%) had total retinal detachment. Successful intraoperative retinal reattachment was achieved in 25 eyes (83%), of which 15 remained attached throughout follow-up; the remaining 10 retinas redetached due to proliferative vitreoretinopathy. Of these patients, 4 subsequently underwent successful reattachment surgery. Among the 19 patients with reattached retinas, final visual acuity was hand motions in 4 eyes, counting fingers in 10 eyes and better than counting fingers in 5 eyes.

The authors concluded that vitreoretinal surgery for primary open globe injury and subsequent repair of retinal detachment can preserve the eye in many cases. This surgery may allow for recovery of some visual function.

Reed DC, Juhn AT, Rayess N, et al. Outcomes of retinal detachment repair after posterior open globe injury. Retina 2016;36:758-763.

Anterior Uveitis and Spondyloarthritis Link

Up to one-third of all patients with spondyloarthritis, including ankylosing spondylitis, inflammatory bowel disease and psoriasis, also show signs of anterior uveitis. Roughly half the patients with anterior uveitis tested positive for the human leukocyte antigen (HLA)-B27 allele; these patients have a higher risk for spondyloarthritis.

Juanola et al from Hospital Universitari de Bellvitge, Spain, reported results from the SENTINEL project, an interdisciplinary, collaborative, prospective study at 66 centers in Spain designed by the Spanish Spondyloarthropathies Study Group of the Spanish Society of Rheumatology. The primary focus of the study was on patients with clinically significant anterior uve-

itis and signs of spondyloarthritis diagnosed by an ophthalmologist.

The study enrolled 798 consecutive patients with ≥ 1 episode of anterior uveitis and an HLA-B27–positive haplotype, or >1 episode of anterior uveitis separated by ≥ 3 months and an HLA-B27–negative haplotype. An ophthalmologist evaluated all patients at baseline and at 3, 6 and 12 months, and a rheumatologist evaluated all patients at baseline and 12 months.

At baseline, 77.8% of patients (mean age, 45 ± 13 years; 59% men) reported back pain before age 45 years, with 44.1% reporting inflammatory back pain, although 60.4% of all patients also reported a good response to nonsteroidal anti-inflammatory drugs. Using the Assessment of SpondyloArthritis International Society criteria, a rheumatologist diagnosed axial spondyloarthritis in 50.2% and peripheral spondyloarthritis in 17.5% of patients previously diagnosed with anterior uveitis. Among patients with axial spondyloarthritis, 60.4% had ankylosing spondylitis.

HLA-B27–positive patients were more likely to report inflammatory back pain ($p < .001$) and arthritis ($p = .009$) than were HLA-B27–negative patients, and were more frequently diagnosed with axial (71.2% vs 19.5%; $p < .001$) and peripheral (21.9% vs 11.1%; $p < .001$) spondyloarthritis. Ophthalmologic measures were similar between the groups for most variables, although the HLA-B27–negative group showed significantly more granulomatous uveitis and vasculitis.

Both anterior uveitis and spondyloarthritis can have a negative effect on a patient's quality of life. The results of this study indicated the need for cooperation and collaboration between ophthalmologists and rheumatologists in patients diagnosed with either of these conditions.

Juanola X, Loza Santamaría E, Cordero-Coma M; SENTINEL Working Group. Description and prevalence of spondyloarthritis in patients with anterior uveitis: the SENTINEL interdisciplinary collaborative project. Ophthalmology 2016;doi:10.1016/j.ophtha.2016.03.010.

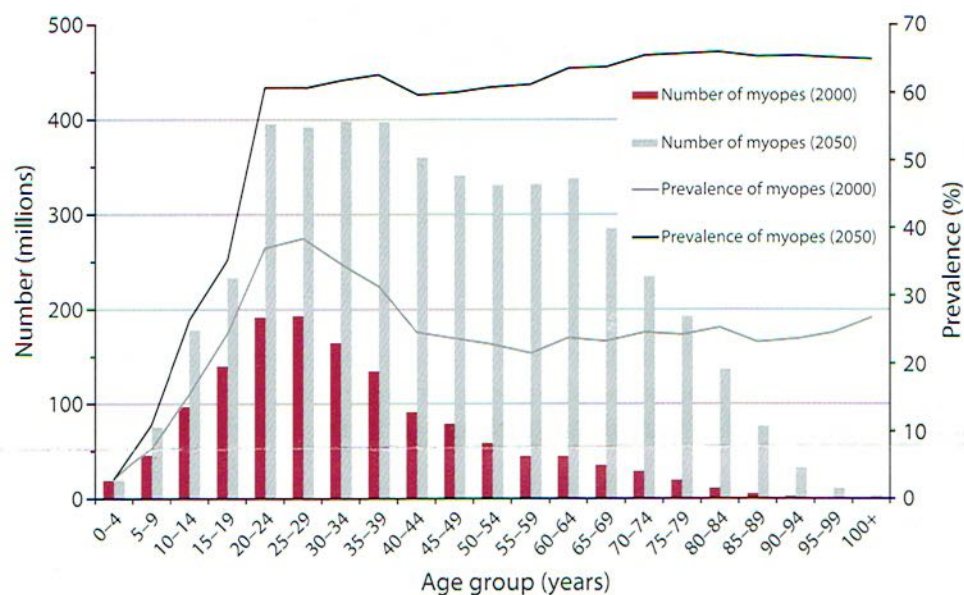


Figure 1. The distribution of people estimated to have myopia between 2000 and 2050.

Trends in Global Myopia and High Myopia Prevalence

The most common cause of distance vision impairment, uncorrected refractive error largely caused by myopia affects 108 million people worldwide. High myopia increases the risk of cataract, glaucoma, retinal detachment and myopic macular degeneration. Holden et al from the University of New South Wales, Australia, undertook a systematic literature review and a meta-analysis of available information relating to localized and global prevalence of myopia. The authors aimed to establish the prevalence of myopia and high myopia, as well as to project changes in myopia prevalence over the next few decades.

Myopia was defined as a spherical equivalent of ≤ -0.50 diopters (D); high myopia was defined as a spherical equivalent of ≤ -5.00 D, a definition commonly used to identify people at higher risk of pathologic myopia. The authors estimated future changes in myopia prevalence based on rates of change over time corrected for the age of the population.

Worldwide myopia prevalence was estimated to have been 1.406 billion in 2000 (22.9% of the global population) and 1.950 billion in 2010 (28.3% of the global population). The authors projected that myopia prevalence will increase to 2.620 billion in 2020 (34.0% of the global population) and to 4.758 billion in 2050 (49.8% of the global population; Figure 1). The greatest rates of myopia will be found in the high-income nations of the Asia-Pacific region and North America, along with the nations of East Asia and Southeast Asia. While in 2000

the greatest prevalence of myopia was among people aged 10 to 39 years old, the authors foresee dramatic increases in myopes aged 10 to 79 years.

Within the high-income region of North America, the prevalence of myopia is expected to increase from 34.5% of the population in 2010 to 58.4% in 2050, with high myopia making up as much as 20% of this group. As the impact of myopia on the older population increases, vision loss from pathologic myopia will become an increasing burden on society.

Holden BA, Fricke TR, Wilson DA, et al. Global prevalence of myopia and high myopia and temporal trends from 2000 through 2050. *Ophthalmology* 2016;123:1036-1042.

Best Timing for Epiretinal Membrane Surgery

Common among people >60 years old, epiretinal membrane (ERM) often has few or no symptoms and limited progression. Studies of large populations have shown that the natural history of ERM is usually benign; however, ERM can lead to loss of vision and/or metamorphopsia in some individuals, and the rate of progression of visual loss in symptomatic

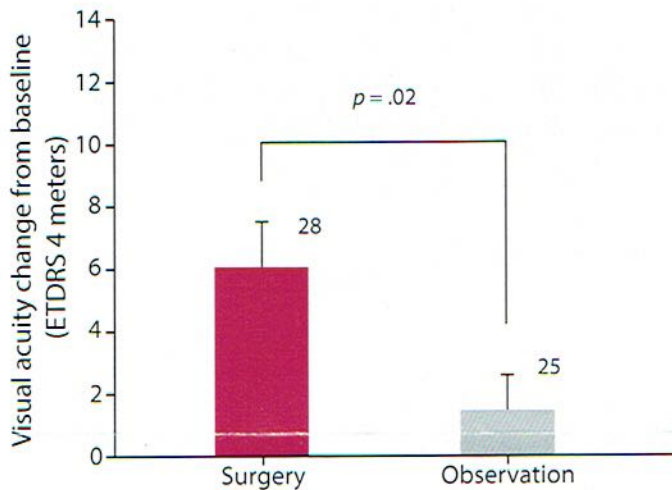


Figure 2. Change in BCVA from baseline to final examination in eyes that underwent surgery for ERM vs eyes that did not during the study. Error bars represent standard error of the mean.

cases remains unknown. Kofod et al from the University of Copenhagen, Denmark, conducted a prospective, randomized controlled clinical trial to find the appropriate timing for surgery in eyes with ERM and acceptable visual acuity.

The study enrolled 53 patients between 2008 and 2011 who showed symptoms of visual loss and metamorphopsia with a duration of <24 months attributed to ERM in 1 eye, verified by ocular coherence tomography (OCT). All patients at baseline had best-corrected visual acuity (BCVA) of ≥ 65 Early Treatment Diabetic Retinopathy Study (ETDRS) letters measured at 4 meters, representing borderline candidates for surgery. These patients were randomized to vitrectomy (follow-up at 1, 3, 6, 9 and 12 months) or watchful waiting (follow-up at 3, 6, 9 and 12 months). At each visit, patients underwent BCVA measurement, a clinical examination that included dilated funduscopy and central macular thickness measured by OCT.

The original randomization created an immediate surgery group of 20 patients and a watchful waiting group of 33 patients. During the 12-month period of the study, 8 patients crossed over from the watchful waiting group to the surgery group. The authors followed the watchful waiting group beyond the end of the follow-up

period and found that >50% of the watchful waiting group patients underwent surgery 3 years later. Neither BCVA at 12 months nor change in BCVA from baseline to 12 months differed significantly between the groups.

However, eyes that underwent surgery showed a significant gain of 6 letters ($p < .001$), while no significant gain was seen in the eyes that did not undergo surgery (Figure 2). Central macular thickness decreased significantly in the operated-upon eyes beginning at 3 months but remained unchanged in the watchful waiting eyes. No complications were reported in the vitrectomy patients.

Visual acuity in the patients who were borderline candidates for ERM surgery remained stable after 1 year of watchful waiting. However, approximately half these patients needed surgery after 3 years. Because the patients who underwent immediate vitrectomy showed a significant gain in vision, the practitioner and patient must decide whether minimal surgical risk outweighs the benefit of immediate surgery.

Kofod M, Christensen UC, la Cour M. Deferral of surgery for epiretinal membranes: is it safe? Results of a randomised controlled trial. Br J Ophthalmol 2016;100:688-692.

WINTER 2017

- Lamellar macular hole
- Sleep disturbance and central serous chorioretinopathy
- Retinal pigment epithelial tears

**In The
Next Issue**